



OPEN ACCESS

Original research

LIQUID - Treatment of high-grade dural arteriovenous fistulas with Squid liquid embolic agent: a prospective, observational multicenter study

Dominik F Vollherbst ,¹ Tobias Boppel,² Marta Wallocha,³ Ansgar Berlis,⁴ Christoph J Maurer ,⁴ Werner Weber,⁵ Sebastian Fischer,⁵ Alexander Bock,⁶ Stephan Meckel,^{7,8} Georg Bohner,⁹ Thomas Liebig,¹⁰ Christian Herweh,¹ Martin Bendszus,¹ René Chapot ,³ Markus A Möhlenbruch¹

For numbered affiliations see end of article.

Correspondence to

Dr Markus A Möhlenbruch, Department of Neuroradiology, Heidelberg University Hospital, 69120 Heidelberg, Germany; markus.moehlenbruch@med.uni-heidelberg.de

Received 9 November 2022

Accepted 19 December 2022

ABSTRACT

Background Endovascular embolization is a feasible treatment for cranial dural arteriovenous fistulas (DAVFs). New embolic agents aim to improve the success of DAVF embolization.

Objective To assess the safety, efficacy, and short-term outcome of the treatment of DAVFs using the new liquid embolic agent Squid.

Methods The LIQUID study is a prospective, observational multicenter study on the treatment of high-grade (Cognard type ≥ 3) DAVFs with the embolic agent Squid. The primary outcome measures were safety (ie, morbidity and mortality), as well as the occlusion rate 90 to 180 days after treatment.

Results In eight centers, 53 patients (mean age 59.8 years, 22.6% female) were treated in 55 treatment sessions. Of the DAVFs, 56.6% were Cognard type III, 41.5% type IV, and 18.9% were ruptured. Squid 18 was used in 83.6% and Squid 12 in 32.7% of the treatments. The overall rate of intraprocedural or postprocedural adverse events (AEs) was 18.2%. Procedure-related AEs resulting in permanent morbidity were observed in 3.6%. One patient (1.8%) died unrelated to the procedure due to pulmonary embolism. The final complete occlusion rate at 90 to 180 days was 93.2%. After a mean follow-up of 5.5 months, the modified Rankin Scale (mRS) score was stable or improved in 93.0%. In one of the patients, worsening of the mRS score was related to the procedure (1.8%).

Conclusion Squid is a safe and effective liquid embolic agent for the treatment of high-grade DAVFs.

INTRODUCTION

Cranial dural arteriovenous fistulas (DAVFs) are pathological connections between dural arteries and dural sinuses or cortical veins. According to their risk of hemorrhage, DAVFs can be divided into low-grade DAVFs with a very low risk of hemorrhage and high-grade DAVFs, which are accompanied by an annual risk of hemorrhage of up to 20%.¹

Endovascular embolization is nowadays considered as the first-line treatment for most DAVFs.^{2,3} The treatment success using this technique has been substantially improved in the last decades by a better understanding of the anatomy and the pathophysiology of DAVFs as well as by the introduction

WHAT IS ALREADY KNOWN ON THIS TOPIC

⇒ Squid is a new liquid embolic agent which aims to improve the treatment of intracranial vascular malformations, such as dural arteriovenous malformations (DAVFs).

WHAT THIS STUDY ADDS

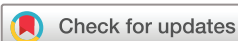⇒ In this prospective, multicenter study, Squid was a safe and effective liquid embolic agent for the treatment of high-grade DAVFs.

HOW THIS STUDY MIGHT AFFECT RESEARCH AND PRACTICE

⇒ Squid, which features several modifications compared with the established agent Onyx, expands the armamentarium of liquid embolic agents for the treatment of DAVFs.

of new endovascular materials, such as embolic agents. For many years, polyvinyl alcohol particles and cyanoacrylates were the only available embolic agents, which were broadly used for DAVF embolization, achieving occlusion rates varying between 30% and 71%.⁴⁻⁸ After the introduction of Onyx (Medtronic Neurovascular, Irvine, USA), a non-adhesive, precipitating liquid embolic agent, the occlusion rates were substantially improved, with occlusion rates of between 76% and 91% in recent studies.^{2,9,10} However, besides several advantages of Onyx over the aforementioned formerly used embolic agents, it also has some potential drawbacks, such as poor visibility during longer injections and impaired penetration into very small blood vessels.^{11,12}

Squid (Balt, Montmorency, France) is a novel non-adhesive, precipitating, liquid embolic agent that was recently introduced. It aims to overcome these shortcomings via specific modifications, such as a very small grain size of the admixed radiopaque tantalum powder and by providing an additional extra-low viscous formulation. Until now, only two retrospective single-center studies with a relatively low case number (9 and 19 patients, respectively) have reported on DAVF embolization with Squid.^{13,14}



© Author(s) (or their employer(s)) 2023. Re-use permitted under CC BY-NC. No commercial re-use. See rights and permissions. Published by BMJ.

To cite: Vollherbst DF, Boppel T, Wallocha M, et al. *J NeuroIntervent Surg* Epub ahead of print: [please include Day Month Year]. doi:10.1136/jnis-2022-019859

The purpose of this study was to prospectively assess the safety, efficacy, and short-term outcome of the treatment of high-grade DAVFs with Squid in a larger multicenter patient cohort.

MATERIALS AND METHODS

Study design

The ‘Treatment of Dural Arteriovenous Fistulas with SQUID Liquid Embolic Agent (LIQUID)’ study is a prospective, observational multicenter study on the liquid embolic agent Squid, which was performed in eight neurovascular centers. A summary of the study protocol was published in the ClinicalTrials.gov database (<https://clinicaltrials.gov/ct2/show/NCT03524976>). Institutional ethic committees approved this study (ethics committee of the Medical Faculty of Heidelberg, reference number: S-319/2016). Informed consent was obtained from the patients, if possible, before the first treatment. If the patient was not able to give informed consent prior to the treatment (eg, in cases of intracranial hemorrhage), the patient’s next of kin or legal representative could give consent. Informed consent was then obtained by the patient as soon as possible, at the latest before hospital discharge. If consent could not be achieved during hospital stay, the patient was excluded from the study.

Inclusion criteria

- ▶ Cranial DAVF with direct cortical venous drainage or spinal perimedullary venous drainage (Cognard type III, IV, or V¹⁵) requiring endovascular treatment.
- ▶ Intention to use Squid exclusively as embolic agent.
- ▶ Age >18 years.
- ▶ The patient agrees with the clinical data collection and medical file access.

Exclusion criteria

- ▶ Low-grade DAVFs (Cognard type I or II).
- ▶ Intention to use an embolic agent other than Squid.
- ▶ DAVFs with any endovascular pretreatment.
- ▶ Pregnancy.

Patient, DAVF, and treatment characteristics

The patient, DAVF, and treatment characteristics were assessed using a systematic electronic case report form.

Patient characteristics included age, sex, and pre-existing comorbidities, as well as DAVF-related symptoms, potential underlying causes for the development of the DAVF, baseline and follow-up modified Rankin Scale (mRS) score, and health-related quality of life, measured using EQ5D. mRS score assessment was performed by an independent neurologist, neuroradiologist, or neurosurgeon.

The following DAVF parameters were recorded: presence of DAVF-related intracranial hemorrhage, location of DAVF,¹⁶ fistula type according to the Cognard classification,¹⁵ signs of venous congestion, venous or arterial aneurysms, involved arterial feeder territories, and the presence of bilateral feeders.

For the treatment characteristics, which could be independently chosen by the treating physician, we assessed the mode of anesthesia, formulation and volume of injected Squid, the microcatheter which was used for embolization, the artery selected for the embolization with Squid, the use of accessory devices such as balloon-catheters and coils, and the overall duration of the procedure.

Outcome parameters

The primary outcome measures were morbidity and mortality, as well as the occlusion rate 90 to 180 days after treatment. The mRS scores at baseline and at follow-up were used to assess morbidity. Pre- and postinterventional EQ5D was compared. DAVF occlusion was assessed by invasive catheter angiography or MRI, with catheter angiography being the preferred imaging modality. The degree of occlusion was classified as ‘complete occlusion’, ‘near complete occlusion >90%’, ‘partial occlusion 50–90%’, ‘partial occlusion <50%’, and ‘no occlusion’. An independent core laboratory (TB) analyzed the pre- and postinterventional images and assessed the degree of occlusion immediately after the treatment and at the 90 to 180 days’ follow-up.

Secondary outcome measures were immediate DAVF occlusion after the first embolization procedure, including immediate occlusion using Squid only, the incidence of Squid deficiencies or malfunctions, such as inadequate visibility, and the occurrence of adverse events (AEs). AEs were rated as ‘mild’, ‘moderate’, ‘severe’, or ‘life-threatening’, and classified according to their relation to Squid, the procedure, and/or the DAVF. The outcome of the AEs was classified as ‘recovered without sequelae’, ‘recovered with sequelae’, ‘not yet recovered’, or ‘death’.

RESULTS

Patient and DAVF characteristics are summarized in [table 1](#). Two example cases are illustrated in [figure 1](#) and [figure 2](#).

Fifty-three patients with a mean age of 60 years, most of them male (77.4%), treated between January 2017 and September 2019, were included in this study. The most frequent comorbidity was arterial hypertension (50.9%). The most frequent symptoms (some patient reported more than one symptom) were headaches (32.1%), followed by seizure (26.4%), tinnitus (13.2%), dizziness (13.2%) and neuropsychiatric disorders (13.2%). Only 17.0% of the lesions were asymptomatic. In most cases (92.5%), no underlying cause for the DAVF was identified.

In 10 patients (18.9%) the DAVF was ruptured, causing intracranial hemorrhage, with intraparenchymal location in nine cases (17.0%) and accompanied by subarachnoid hemorrhage in four cases (7.5%). One patient presented with isolated subarachnoid hemorrhage (1.9%). The most frequent DAVF location was the superior sagittal sinus (24.5%), followed by the transverse sinus (20.8%), the torcular (15.1%), and the tentorium (15.1%). Most DAVFs were classified as Cognard type III (56.6%). The middle meningeal artery (64.2%), the occipital artery (37.7%), and the posterior meningeal artery (15.1%) were the most frequently involved feeding arteries. Bilateral feeders were present in 28.3% and pial arteries were involved in only 5.7%.

Treatment characteristics and outcome parameters are summarized in [table 2](#).

In total, 55 treatments were performed (two patients had two treatment sessions). All patients were treated under general anesthesia and via transfemoral access. Transarterial embolization was the primary treatment technique in all cases. Squid 18 was injected in 83.6% and Squid 12 in 32.7% of the treatments. The most frequently used artery for embolization was the middle meningeal artery (66.1%), followed by the occipital artery (14.3%), and the ascending pharyngeal artery (7.1%). In 10.9% of the treatments, Squid 12 was used as the only embolic agent. The two most frequently used microcatheters were the Marathon (Medtronic; 61.1%) and the Scepter XC balloon catheter (MicroVention, Aliso Viejo, USA; 13.9%). Accessory devices were used in 32.7% (21.8% balloon-assisted embolization, 5.5% balloon protection of healthy arterial blood vessels, and 5.5% coiling). The balloon-assisted embolizations were performed

Table 1 Patient and dural arteriovenous fistula characteristics

Patient characteristics					
Number of patients	53				
Age (years)	59.8±12.8 (30–83)				
Sex	Female 22.6%	Male 77.4%			
Comorbidities	Arterial hypertension 50.9%	Diabetes mellitus 15.1%	Previous stroke 11.3%	CAD 9.4%	
Symptoms	Headache 32.1%	Seizure 26.4%	Tinnitus 13.2%	Dizziness 13.2%	
	Neuropsychiatric 13.2%	Paresis 7.6%	Paresthesia 5.7%	Asymptomatic 17.0%	
Suspected underlying cause for DAVF	Unknown 92.5%	Trauma 3.8%	Sinus thrombosis 1.9%	Coagulopathy 1.9%	
Baseline mRS score	0 17.0%	1 45.3%	2 18.9%	3 3.8%	4 9.4%
5 5.7%					
DAVF characteristics					
Hemorrhage	Yes 18.9%		No 81.1%		
Location	Superior sagittal sinus 24.5%	Transverse sinus 20.8%	Torcular 15.1%	Tentorium 15.1%	
	Temporal bone 5.7%	Lesser sphenoid wing 5.7%	Sigmoid sinus 5.7%	Other* 7.6%	
Cognard type	III 56.6%	IV 41.5%	V 1.9%		
Involved arterial feeder territories	Middle meningeal a 64.2%	Occipital a 37.7%	Posterior meningeal a 15.1%	Ascending pharyngeal a 9.4%	
	Superficial temporal a 7.6%	Internal carotid a† 5.7%	Pial a‡ 5.7%	Bilateral feeders 28.3%	
Additional findings	Venous congestion 37.7%	Venous aneurysms 17.0%	Arterial aneurysms§ 1.9%		

*Superior petrosal sinus (3.8%), skull base (1.9%), and frontobasal (1.9%).
†Dural branches.
‡Supply by pial arteries.
§Directly related to the fistula.
a, artery; CAD, coronary artery disease; DAVF, dural arteriovenous fistula; mRS, modified Rankin Scale.

using the Scepter XC (81.8%), Scepter Mini (MicroVention; 9.1%), or Eclipse 2 L (Balt; 9.1%). Of the three coiling cases, transvenous coiling was performed in two, either after partial transarterial embolization or after complete embolization for stabilization of the occlusion. In the third case, coils were used for the pressure-cooker technique. The mean duration of a single treatment procedure was 125 min.

AEs occurred during or after 10 (18.2%) treatments, consisting of two (3.6%) intraprocedural complications (dissection and microcatheter rupture) and eight (14.6%) postprocedural complications (two cases of groin hematomas and seizures, respectively, and one case of intracerebral hemorrhage, pulmonary embolism, pneumonia, and visual disturbances, respectively). The rate of severe or life-threatening AEs was 5.5% (one case of intracerebral hemorrhage, pulmonary embolism, and seizure, respectively). Of the patients who developed AEs, 7/10 recovered without sequelae, while 1/10 recovered with sequelae, 1/10 did not yet recover, and 1/10 died. The patient who died had a fatal pulmonary embolism, unrelated to the procedure, 4 days after the treatment. In that patient, no specific reason for the embolism was found and no radiopaque embolic agent was detected within the pulmonary arteries in the chest CT, but the patient had multiple vascular risk factors, such as obesity, heart failure, and arterial hypertension.

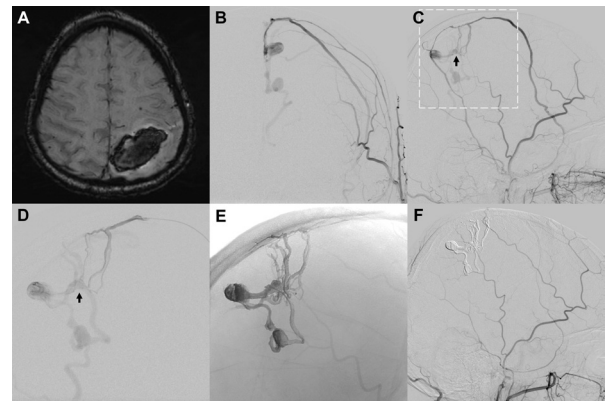


Figure 1 Treatment of a ruptured dural arteriovenous fistula (DAVF) near the superior sagittal sinus with Squid 18. Example of a patient who developed an intracranial hemorrhage in the left parietal lobe (A; susceptibility-weighted MRI) due to rupture of a Cognard type IV DAVF near the superior sagittal sinus. In an angiogram of the left external carotid artery (B, C) feeders of the DAVF from the middle meningeal artery can be identified. The frontal feeder was catheterized with a marathon microcatheter. A superselective angiogram of the fistula is shown in (D). After positioning of the microcatheter near the fistula point (black arrow in C and D), complete embolization using Squid 18 was achieved (embolic agent cast visualized in E). (F) The angiogram 3 months after the treatment shows complete occlusion of the DAVF.

Procedure-related AEs resulting in permanent morbidity were observed in 3.6% (one case of postinterventional hemorrhage of the DAVF and one case of visual disturbances (blurry vision and scotoma) due to focal edema adjacent to the fistula point). The intracerebral hemorrhage, which was located in the temporal

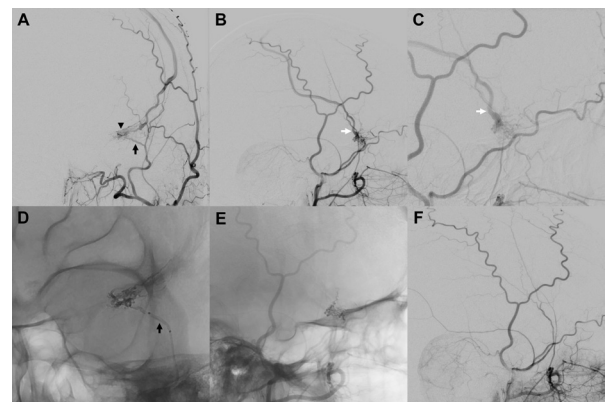


Figure 2 Balloon-assisted embolization of a symptomatic dural arteriovenous fistula (DAVF) at the lesser sphenoid wing with Squid 12. Example of a patient who presented with a seizure. Angiography of the external carotid artery (A–C) showed a DAVF at the lesser sphenoid wing with feeders from the ipsilateral middle meningeal artery (black arrow in (A)), supplying a fine fistula network (black arrowhead in (A)) and draining into a slightly enlarged cortical vein (white arrows in B and C). The feeder was catheterized with a Scepter mini balloon catheter (black arrow in D), and balloon-assisted embolization was performed using Squid 12, which was chosen as embolic agent owing to the small vessels of the fistula network. No inadvertent embolization of adjacent critical vessels, such as the recurrent meningeal/ophthalmic artery, was observed. The embolic agent cast after complete embolization is shown in (E). The angiogram 5 months after the treatment shows complete occlusion of the DAVF.

Table 2 Treatment characteristics and outcome parameters

Treatment characteristics						
Number of treatments	55					
Treatments per DAVF	One treatment per DAVF 96.4%			Two treatments per DAVF 3.6%		
Formulation of Squid	Squid 12 32.7%		Squid 18 83.6%		Squid 18 LD 1.8%	
Volume of Squid per embolization (mL)	1.3±1.2 (0.1–7.5)					
Artery selected for embolization	Middle meningeal a 66.1%	Occipital a 14.3%	Ascending pharyngeal a 7.1%	Pial a 5.4%	Posterior meningeal a 3.6%	Superficial temporal a 3.6%
Microcatheter used for embolization	Marathon 61.1%	Scepter XC 13.9%	Apollo 11.1%	Sonic 5.6%	Others 8.3%	
Accessory devices	Balloon-assisted embolization 21.8%		Balloon-assisted protection* 5.5%		Coiling† 5.5%	
Duration of the procedure (min)	125±51 (40–235)					
Morbidity and adverse events‡						
mRS score at follow-up§	0 55.8%	1 20.9%	2 9.3%	3 4.7%	4 4.7%	5 2.3%
Morbidity at 90 to 180 days§	Overall rate of mRS score decline 7.0%			mRS score decline related to the procedure 2.3%		
Frequency of adverse events	Overall 18.2%		Intraprocedural 3.6%		Postprocedural 14.6%	
Specification of adverse events	Seizure 3.6%		Groin hematoma 3.6%		Pulmonary embolism 1.8%	
	Dissection 1.8%		Microcatheter rupture 1.8%		Pneumonia 1.8%	
			Visual disturbances 1.8%		Intracranial hemorrhage 1.8%	
Adverse event severity	Mild 5.5%		Moderate 7.3%		Severe 1.8%	
			Life-threatening 3.6%			
Relatedness of adverse events	Not related to Squid 12.7%		Probably related to Squid 0%		Definitely related to Squid 5.5%	
	Not related to procedure 5.5%		Probably related to procedure 1.8%		Definitely related to procedure 10.9%	
	Not related to DAVF 7.3%		Probably related to DAVF 1.8%		Definitely related to DAVF 9.1%	
Treatment of adverse events	Medical 9.1%		Surgical 1.8%		Endovascular 3.6%	
					None 3.6%	
Outcome of adverse events	Recovered w/o sequelae 12.7%		Recovered w/ sequelae 1.8%		Not yet recovered 1.8%	
					Death 1.8%	
Degree of DAVF occlusion¶						
Overall immediate occlusion rate	Complete occlusion 94.3%		Near-complete occlusion>90% 3.8%		Partial occlusion 50–90% 1.9%	
					Partial occlusion <50% 0%	
Immediate occlusion rate using Squid only	Complete occlusion 92.5%		Near-complete occlusion>90% 3.8%		Partial occlusion 50–90% 1.9%	
					Partial occlusion <50% 1.9%	
Final occlusion rate at 90 to 180 days**	Complete occlusion 93.2%		Near-complete occlusion>90% 2.3%		Partial occlusion 50–90% 2.3%	
					Partial occlusion <50% 2.3%	
*Protection of a healthy brain-supplying artery to avoid inadvertent embolization.						
†Transvenous coiling of the draining vein (n=2) or pressure-cooker technique (n=1).						
‡Relative frequencies indicated related to the number of treatments (n=55).						
§Clinical follow-up was available for 43 patients.						
¶Occlusion rates indicated related to the number of DAVFs (n=53).						
**Imaging follow-up was available for 44 patients.						
a, artery; DAVF, dural arteriovenous fistula; mRS, modified Rankin Scale.						

lobe, adjacent to the fistula, occurred after the complete embolization of a Cognard type III DAVF at the transverse sinus and was treated with craniotomy and hematoma evacuation and the

patient recovered with only mild residual symptoms and an mRS score of 0 at the latest follow-up. No specific reason for the hemorrhage could be found. The symptoms of the patient with

visual disturbances partially resolved with an mRS score of 1 at the latest follow-up.

Squid-related AEs resulting in permanent morbidity were observed in 3.6% (the above-mentioned cases of hemorrhage and visual disturbances). After a mean clinical follow-up of 5.3 months, which was available for 43 patients, the mRS score was stable or improved in 93.0%. Of the patients with worsening mRS, only one case (1.8%; visual disturbances, see above) was related to the procedure.

Pre- and postinterventional EQ5D was available for 37 patients (69.8%). Improvement was observed in 16.2% for mobility, in 13.5% for self-care, in 32.4% for usual activities, in 40.5% for pain/discomfort, in 16.2% for anxiety and in 73.0% for the Visual Analog Scale. Deterioration was observed in 0% for mobility and self-care, respectively, in 2.7% for usual activities, in 10.8% for pain/discomfort, in 5.4% for anxiety and in 8.1% for the Visual Analog Scale.

The immediate complete occlusion rate using Squid only was 92.5%. In one patient, after partial embolization with Squid, transvenous coiling was performed for complete occlusion, resulting in an overall immediate complete occlusion rate of 94.3%. Imaging follow-up was available for 43 patients (90.7% invasive catheter angiography, 9.3% MRI) and the mean imaging follow-up time was 5.5 months. One patient showed spontaneous complete occlusion after 'near-complete occlusion >90%'. Another patient's DAVF progressed from an immediate 'near-complete occlusion >90%' to 'partial occlusion <50%' during the follow-up period. Two patients developed a recurrence of their DAVF after immediate complete occlusion. The rate of complete occlusion at 90 to 180 days' follow-up imaging was 93.2%.

DISCUSSION

In this prospective multicenter study, Squid was a safe and effective agent for the embolization of cranial high-grade DAVFs, demonstrated by a low procedure-related permanent morbidity rate of 3.6% and a high overall occlusion rate of 93.2% at 90 to 180 days' follow-up.

The overall rate of AEs was 18.2% in this study, which is relatively high, compared with studies reporting on DAVF embolization using Onyx.^{2,9,10} However, this study focused exclusively on high-grade DAVFs, and the rate of procedure-related AEs resulting in permanent morbidity was only 3.6%. These rates are similar to those reported in previous studies. A meta-analysis on transarterial embolization of DAVF (high- and low-grade) with Onyx, which included 19 studies, involving 426 patients, showed similar complication rates, with a pooled procedure-related neurologic deficit rate of 4%, morbidity rate of 3%, and mortality rate of 0%.⁹ Another possible explanation for the higher AE rate in this cohort is the prospective design of the study. In retrospective analyses, cases with complications might be afflicted by selection and observation bias.

The overall core-laboratory-rated occlusion rate of 93.2% in this series is slightly higher than previously published occlusion rates on endovascular embolization of DAVFs. Recent studies on DAVF embolization using Onyx achieved occlusion rates varying between 55% and 91%.^{2,10,17} In the above-mentioned meta-analysis, the pooled initial complete occlusion rate was 82%.⁹ The two studies which were published on DAVF embolization with Squid achieved occlusion rates of 66% and 87%, with the latter focusing on Squid 12 only.^{13,14} The high occlusion rate which was achieved in our study is satisfactory and promising. Nevertheless, it is debatable if our occlusion rate can be directly attributed to the use of Squid. The potential advantages,

which are discussed below, might contribute to a more effective embolization, but there was no direct comparison with Onyx or another embolic agent in this study. Furthermore, the centers which participated in this study were specifically selected high-volume centers with a lot of experience in DAVF embolization, and the study had a potential selection bias given its prospective design (difficult-to-treat lesions might not have been included) which are possible confounders for the observed occlusion rate in the LIQUID study.

The two major innovations of the new liquid embolic Squid in comparison with Onyx are the size of the tantalum grains which are admixed to the agent and the availability of the low viscosity version Squid 12. Besides that, the components of Squid are identical to those of Onyx: ethylene vinyl alcohol copolymer, tantalum powder, and dimethyl sulfoxide.

Tantalum provides the radiopacity of Squid and Onyx. To create a homogeneous suspension, it is recommended that the agents are kept on a shaker for at least 20 min before the injection. However, after some time the tantalum particles begin to sediment within the syringe and also within the microcatheter, which might impair the visibility during longer embolization procedures or lead to inadvertent occlusion of the microcatheter. To overcome this drawback, the grains of the tantalum powder in Squid are smaller, which leads to a slowdown of this sedimentation process, potentially extending the time of adequate visibility and lowering the risk of microcatheter occlusion. The slower sedimentation and prolonged visibility were confirmed in an experimental study.¹⁸ However, this issue has not yet been addressed in clinical studies. In our study, no case of inadequate visibility occurred, and one case of microcatheter rupture was reported. No specific reason, such as sedimentation of the embolic agent leading to clogging of the microcatheter, was found to be responsible for this rupture.

For many years, Onyx 18 was the least viscous copolymer-based, non-adhesive embolic agent on the market. The low-viscosity version Squid 12, which was successfully used in 32.7% of the procedures in this study, expands the armamentarium of liquid embolic agents which can be used for the embolization of DAVFs. The lower viscosity can potentially enhance the penetration of the vascular network of a DAVF, especially of very small blood vessels, and thus improve the chance of occlusion. Experimental studies have already shown that embolization using the low viscosity agents Squid 12 and PHIL LV (MicroVention) can be more effective than embolization with the standard viscosity agents Onyx 18 and PHIL 25%.^{12,19} In this study, Squid 12 was not directly compared with Squid 18 but it was effectively and safely used in nearly one-third of all embolization procedures. One possible embolization strategy is starting the embolization with Squid 18 until a relevant increase of the injection pressure is noted, and then switching to Squid 12. This technique can help to maintain forward flow within the fistula network and thus improve the embolization success.

Despite their potential advantages, embolization with low-viscosity agents have three major drawbacks, which should be considered when using Squid 12. These drawbacks were not directly observed in this study but should be known by the interventionalists who use Squid 12. First, due to the low viscosity, a plug formation, which is often mandatory for effective embolization using the plug-and-push technique,^{20,21} can be impeded, and thus potentially lead to a high amount of reflux. This reflux, besides resulting in a potentially ineffective embolization, risks causing a neurologic deficit, such as cranial nerve palsies, if the inadvertently embolized vessels are of important nutritive nature.²² The use of a balloon catheter or the pressure-cooker

technique²³ can help to overcome this drawback. The second conceivable disadvantage of Squid 12 is early distal embolization, which is more relevant for arteriovenous malformation treatments, as it bears the risk of premature closing of the draining vein, which can eventually lead to intraprocedural or postprocedural hemorrhage. For DAVFs this aspect is lesser relevant, but nevertheless, the interventionalist should be aware of the higher risk of early distal embolization when using the low viscous Squid 12. The third drawback is a potential higher ability to diffuse into collateral meningeal arteries due to the lower viscosity, which may lead to a higher risk for ischemic strokes.

We acknowledge that this study has noteworthy limitations. The number of patients who were analyzed in this study is relatively low compared with larger studies reporting on DAVF embolization using Onyx. Furthermore, 9.3% of the patients were not available for follow-up, limiting the data for the assessment of the outcome parameters of this study. However, this is the largest study reporting on DAVF embolization using Squid until now. Furthermore, this is the first ever prospective study on the endovascular treatment of high-grade DAVFs in the era of liquid embolic agents. Another limitation is the lack of a control group in which other embolic agents were used. Therefore, a comparison of Squid with other embolic agents regarding occlusion and complication rates, as well as potential advantage or disadvantages, was limited.

CONCLUSION

Squid is a promising liquid embolic agent for the embolization of high-grade DAVFs. In this prospective multicenter study, embolization using Squid was associated with an acceptable complication rate and a high occlusion rate.

Author affiliations

¹Department of Neuroradiology, Heidelberg University Hospital, Heidelberg, Germany

²Institute of Neuroradiology, University Hospitals Schleswig-Holstein, Campus Lübeck, Luebeck, Germany

³Neuroradiology, Alfried Krupp Krankenhaus Ruttenscheid, Essen, Germany

⁴Department of Diagnostic and Interventional Neuroradiology, Universitätsklinikum Augsburg, Augsburg, Germany

⁵Department of Neuroradiology, Universitätsklinikum Knappschaftskrankenhaus Bochum, Bochum, Germany

⁶Department of Neuroradiology, Vivantes Hospital, Berlin, Germany

⁷Department of Neuroradiology, University of Freiburg, Freiburg, Germany

⁸Institute of Diagnostic and Interventional Neuroradiology, RKH Kliniken Ludwigsburg, Ludwigsburg, Germany

⁹Department of Neuroradiology, University Hospital of Berlin (Charité), Berlin, Germany

¹⁰Institute of Diagnostic and Interventional Neuroradiology, University Hospital, LMU Munich, Munchen, Germany

Correction notice Since this article published online, the mRS score data in table 2 has been reformatted for clarity.

Contributors All listed authors contributed to the work and approved the final manuscript. DFV and MAM acquired, analyzed, and interpreted data for the work; drafted the manuscript and approved the final manuscript. MAM designed the study and is the guarantor of this work. TB was responsible for the independent imaging core lab. MW, ABe, CM, WW, SF, ABo, SM, GB, TL, CH, MB, and RC acquired and analyzed data for the work. MAM is the guarantor.

Funding This is an investigator-initiated study. The Department of Neuroradiology, Heidelberg University Hospital received a scientific grant from Balt (Montmorency, France). The contributing centers received a case fee for each patient who was included in the study. Balt did not have an influence on the study design, data collection, analysis, and writing of the manuscript.

Competing interests DFV reports consultancy for Medtronic and paid lectures for Cerenovus, and a research grant by MicroVention (unrelated to this work). TB reports payment for lectures and presentations from Stryker, Penumbra, and support for attending meeting and/or travel from Phenox, Microvention, and Stryker in the last 3 years. ABe reports proctoring for Microvention, Stryker, and Medtronic; payments for lectures for Stryker, Phenox and Penumbra; and board

fees for CEC (Phenox) and Bayer. SM reports consultancy for Stryker, Medtronic, Acandis GmbH, Novartis Pharma GmbH (unrelated to study) and a travel grant by Balt (unrelated to study). TL has proctored and consulted for CERUS, Stryker, Phenox, Acandis, Medtronic, Pfizer and Microvention within the past three years but has no direct conflict of interest in the realm of this study. MB reports the following conflicts of interest outside the present work: board membership: DSMB Vascular Dynamics; consultancy: Roche, Guerbet, Codman; grants/grants pending: DFG, Hopp Foundation, Novartis, Siemens, Guerbet, Stryker, Covidien; payment for lectures (including service on speakers bureaus): Novartis, Roche, Guerbet, Teva, Bayer, Codman. MAM has received consulting honoraria, speaker honoraria, and travel support outside this work from Codman, Covidien/Medtronic, MicroVention, Phenox, and Stryker. The other authors declared no specific conflict of interest.

Patient consent for publication Not applicable.

Ethics approval This study involves human participants and was approved by the ethics committee of the Medical Faculty of the University of Heidelberg (reference number: S-319/2016) Participants gave informed consent to participate in the study before taking part.

Provenance and peer review Not commissioned; externally peer reviewed.

Data availability statement All data relevant to the study are included in the article or uploaded as supplementary information. Nor applicable.

Supplemental material This content has been supplied by the author(s). It has not been vetted by BMJ Publishing Group Limited (BMJ) and may not have been peer-reviewed. Any opinions or recommendations discussed are solely those of the author(s) and are not endorsed by BMJ. BMJ disclaims all liability and responsibility arising from any reliance placed on the content. Where the content includes any translated material, BMJ does not warrant the accuracy and reliability of the translations (including but not limited to local regulations, clinical guidelines, terminology, drug names and drug dosages), and is not responsible for any error and/or omissions arising from translation and adaptation or otherwise.

Open access This is an open access article distributed in accordance with the Creative Commons Attribution Non Commercial (CC BY-NC 4.0) license, which permits others to distribute, remix, adapt, build upon this work non-commercially, and license their derivative works on different terms, provided the original work is properly cited, appropriate credit is given, any changes made indicated, and the use is non-commercial. See: <http://creativecommons.org/licenses/by-nc/4.0/>.

ORCID iDs

Dominik F Vollherbst <http://orcid.org/0000-0002-8992-4757>

Christoph J Maurer <http://orcid.org/0000-0002-0305-0797>

René Chapot <http://orcid.org/0000-0002-2584-8361>

REFERENCES

- Gross BA, Du R. The natural history of cerebral dural arteriovenous fistulae. *Neurosurgery* 2012;71:594–603.
- Gross BA, Albuquerque FC, Moon K, et al. Evolution of treatment and a detailed analysis of occlusion, recurrence, and clinical outcomes in an endovascular library of 260 dural arteriovenous fistulas. *J Neurosurg* 2017;126:1884–93.
- Ramos S, Bortolotti C, Lanzino G. Endovascular management of intracranial dural arteriovenous fistulae. *Neurosurg Clin N Am* 2014;25:539–49.
- Kim DJ, Willinsky RA, Krings T, et al. Intracranial dural arteriovenous shunts: transarterial glue embolization—experience in 115 consecutive patients. *Radiology* 2011;258:554–61.
- Guedin P, Gaillard S, Boulin A, et al. Therapeutic management of intracranial dural arteriovenous shunts with leptomeningeal venous drainage: report of 53 consecutive patients with emphasis on transarterial embolization with acrylic glue. *J Neurosurg* 2010;112:603–10.
- Miyamoto N, Naito I, Shimizu T, et al. Efficacy and limitations of transarterial acrylic glue embolization for intracranial dural arteriovenous fistulas. *Neurol Med Chir* 2015;55:163–72.
- Berthelsen B. Embolization of dural arteriovenous fistulas draining into the transverse or sigmoid sinus. *Eur Radiol* 1992;2:452–8.
- Baltsavias G, Valavanis A. Endovascular treatment of 170 consecutive cranial dural arteriovenous fistulae: results and complications. *Neurosurg Rev* 2014;37:63–71.
- Sadeh-Gonik U, Magand N, Armoiry X, et al. Transarterial Onyx embolization of intracranial dural fistulas: a prospective cohort, systematic review, and meta-analysis. *Neurosurgery* 2018;82:854–63.
- Vollherbst DF, Herweh C, Schönenberger S, et al. The influence of angioarchitectural features on the success of endovascular embolization of cranial dural arteriovenous fistulas with Onyx. *AJNR Am J Neuroradiol* 2019;40:2130–6.
- Jiang YY, Jo Y-E, Woo JM, et al. In vitro quantification of the radiopacity of Onyx during embolization. *Neurointervention* 2017;12:3–10.
- Vollherbst DF, Otto R, Hantz M, et al. Investigation of a new version of the liquid embolic agent PHIL with extra-low viscosity in an endovascular embolization model. *AJNR Am J Neuroradiol* 2018;39:1696–702.

- 13 Akmangit I, Daglioglu E, Kaya T, *et al.* Preliminary experience with Squid: a new liquid embolizing agent for AVM, AV fistulas and tumors. *Turk Neurosurg* 2014;24:565–70.
- 14 Lozupone E, Bracco S, Trombatore P, *et al.* Endovascular treatment of cerebral dural arteriovenous fistulas with Squid 12. *Interv Neuroradiol* 2020;26:651–7.
- 15 Cognard C, Gobin YP, Pierot L, *et al.* Cerebral dural arteriovenous fistulas: clinical and angiographic correlation with a revised classification of venous drainage. *Radiology* 1995;194:671–80.
- 16 Geibprasert S, Pereira V, Krings T, *et al.* Dural arteriovenous shunts: a new classification of craniospinal epidural venous anatomical bases and clinical correlations. *Stroke* 2008;39:2783–94.
- 17 Li Y, Chen SH, Guniganti R, *et al.* Onyx embolization for dural arteriovenous fistulas: a multi-institutional study. *J Neurointerv Surg* 2022;14. doi:10.1136/neurintsurg-2020-017109. [Epub ahead of print: 25 02 2021].
- 18 Mason JR, Dodge C, Benndorf G. Quantification of tantalum sedimentation rates in liquid embolic agents. *Interv Neuroradiol* 2018;24:574–9.
- 19 Samaniego EA, Derdeyn CP, Hayakawa M, *et al.* In vivo evaluation of the new PHIL low viscosity in a swine rete mirabile model. *Interv Neuroradiol* 2018;24:706–12.
- 20 Mounayer C, Hammami N, Piotin M, *et al.* Nidal embolization of brain arteriovenous malformations using Onyx in 94 patients. *AJNR Am J Neuroradiol* 2007;28:518–23.
- 21 Cekirge S, Saatci I, Arat A. Long intranidal Onyx injections in the endovascular treatment of pial brain AVMs: description of a new technique and philosophy aimed at cure. *J Neurosurg* 2002;96.
- 22 Lee JM, Whang K, Cho SM, *et al.* Cranial nerve palsy after Onyx embolization as a treatment for cerebral vascular malformation. *J Cerebrovasc Endovasc Neurosurg* 2017;19:189–95.
- 23 Chapot R, Stracke P, Velasco A, *et al.* The pressure cooker technique for the treatment of brain AVMs. *J Neuroradiol* 2014;41:87–91.